

Oral Hygiene for Children with Barth syndrome

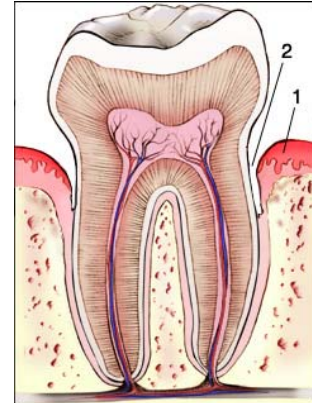
Shelley Bowen, BSF President

Richard I. Kelley, PhD, MD

Shelia Mann, RDH

Good Oral hygiene is very important for the health of a Barth individual, but is often difficult to maintain due to complications caused by neutropenia. Many cases of neutropenia are diagnosed because of chronic or recurrent dental problems. Neutrophils serve as the first line of defense to bacterial infections when a break in a cutaneous or mucosal barrier (inner tissue lining) occurs.

Neutropenia can be cyclical or chronic and can be serious for those who have Barth syndrome. Some individuals may pass through many cycles of neutropenia for years without problems, while others may have aphthous ulcers with every neutropenic period. For many patients with cyclical neutropenia, there is a predictable pattern of oral ulcers, cervical lymphadenopathy (swollen lymph nodes in the neck) and painful gingivitis about every three weeks, coinciding with the low point in the neutropenic cycle. Gingivitis, periodontal disease, and the loss of permanent teeth are common problems across the spectrum of neutropenic syndromes. Most patients with an absolute neutrophil count (ANC) persistently less than 500 have problems with gingivitis and increased periodontal disease, despite good efforts at oral hygiene. These problems can be attributed to a loss of the natural bacteria-killing function in the oral tissues caused by the deficiency of neutrophils, which normally migrate to the gingival crypts where bacteria tend to proliferate. As a result, good dental hygiene is extremely important in overall care of a Barth individual to decrease the potential for infection.



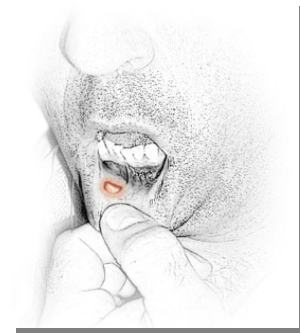(1) Inflammation of the gum tissue causes recession from the tooth, which ultimately results in (2) bone loss.

The quality of life of the patient with severe chronic neutropenia can be severely compromised by chronic oropharyngeal inflammation, recurrent skin and soft tissue infections, or, for more severely affected individuals, repeated hospitalizations for treatment of fever and deep tissue infections. For essentially all patients with severe neutropenia, recurring episodes of fever and illness with lost days from work and school are chronic problems, despite antibiotic treatment.¹

Aphthous Ulcers

Aphthous ulcers (“canker sores”) occur in some individuals who have Barth syndrome. These mouth ulcers are extremely painful and can affect one’s ability to eat. Parents of young children with Barth syndrome must begin oral hygiene early in life by wiping the excess food from the mouth and oral recesses after feedings. Careful inspection of the tissues at these times will aid in recognizing these painful ulcers.

Aphthous ulcers may develop in response to mouth injury such as overly aggressive tooth cleaning or almost any dental procedure. Parents should make sure that their children are brushing properly, but not too hard. Always use a soft bristle toothbrush to avoid scratching the gums and other oral tissues. Ulcers can also occur at the site of injury where the tongue, cheek, or lip is bitten. Stress, dietary deficiencies (especially deficiencies of iron, folic acid, and B vitamins), and food allergies also can trigger ulcers. Ulcers occur most commonly during or following viral infections, but also can occur with no identifiable cause. Local anesthetics may be dabbed onto these ulcers prior to meals if the ulcers are severe enough to interfere with eating.



Oral Hygiene Fact Sheet

The Barth Syndrome Foundation www.barthsyndrome.org

2 May 2008/ CAB, RIK

1

DISCLAIMER: This fact sheet is designed for educational purposes only and is not intended to serve as medical advice. The information provided here should not be used for diagnosing or treating a health problem or disease. It is not a substitute for professional care.

It is important to document and report oral ulcers to your physician when they occur, because an ulcer can be a sign of a low point in a neutropenic cycle. When frequent and severe enough to cause weight loss, aphthous ulcers associated with neutropenia are sometimes treated by giving injections of granulocyte colony stimulating factor (G-CSF), a natural hormone that increases the neutrophil count by stimulating the bone marrow. G-CSF may be given every day if the cycles of ulcers and neutropenia are very predictable, only during the expected period of ulceration. However, because G-CSF can have side effects, such as enlargement of the spleen and bone pain, its benefits and risks must be weighed carefully in consultation with your physician.

Treatments and Pain Relief for Mouth Ulcers:

Always consult with a physician before administering any of these medications

- To reduce inflammation, your physician may prescribe topical or oral corticosteroids. Kenalog in Orabase™ is a topical corticosteroid commonly used.
- A prescription of 2% viscous Xylocaine™ solution may be prescribed and applied directly to the sore with a cotton swab. After the sores are dry, apply Zilactin™ medicated gel, which can be purchased in any pharmacy.
- A prescription of Maalox™(one part), Benadryl™ (one part), and Viscaine™ Xylocaine™ (one part) may be prescribed. Mix then rinse mouth and spit out solution.
- Colgate Orabase™ Soothe-N-Seal Gel™ (a liquid formula with applicator that forms a barrier to promote natural healing)
- Colgate Orabase™ with Benzocaine (temporary relieves pain, and shields from further irritation)
- Colgate Peroxyl™ rinse (antiseptic rinse that has bubbling action to clean and alleviate discomfort to promote healing)
- UlcerEase™ Anesthetic Mouth rinse (or similar product). Follow directions listed on the product.
- Warm salt water rinses (1/2 teaspoon salt in 1/2 cup of water)
- Apply hydrogen peroxide (1 part hydrogen peroxide and one part water with a cotton swab) on the canker sore. Then dab a small amount of Milk of Magnesia™ on the ulcer 3-4 times a day. This is not only soothing, but also appears to speed healing.

Additional Tips:

- Avoid hot, spicy, salty, or citrus foods and carbonated beverages to minimize discomfort.
- Take a good multi-vitamin with minerals and eat a well-balanced diet.

Toothpaste

- Sodium Lauryl Sulfate (SLS) is an ingredient in certain toothpastes and mouthwashes known to cause to aphthous ulcers or canker sores. The harshness of this chemical has been proven to create microscopic damage to the oral tissue which lines the inside of your mouth, which then leads to aphthous ulcers.
 - Recommendations for SLS Free Toothpaste:
 - Sensodyne® Original and ProNamel
 - Squigle Enamel Saver
 - Biotene™ Toothpaste for Dry Mouth
 - CloSYS Toothpaste
 - Natural Dentist® Toothpaste
 - Oral B Rembrandt™ Canker Sore Toothpaste

- Avoid toothpastes that contain whitening or tarter control agents. These often have more fluoride or abrasives, which tend to burn or make the gums tingle and can trigger a mouth ulcer to begin. Low-abrasive toothpaste without whitening properties or even a child's toothpaste sometimes works best.

Mouth Washes

- Mouthwash will reduce particulate matter and bacteria in the mouth. Use non-irritating neutral washes, or Hydrogen Peroxide. The bottle will have instructions for a ½ water and ½ Hydrogen Peroxide mixture.
- Avoid commercial mouthwashes and products that contain alcohol, which are very drying.
- Prescription mouth rinses like Peridex™ or PerioMed™ may be recommended by your dentist, if needed.

Dental Care for the Heart Patient

There are specific aspects of dental care that could, in some patients, affect the heart. Dental procedures with patients who have a heart condition should be taken very seriously. Patients with Barth syndrome should advise their dentists of their condition.

Most dentists will ask a patient to complete a checklist prior to any dental care. Patients with heart murmurs, mitral regurgitation, or artificial heart valves are at increased risk of developing endocarditis, a serious infection of the heart valves, and must take precautions prior to any procedure that could introduce bacteria into the bloodstream. The patient with Barth syndrome should consult with his physician for recommendations on the use of prophylactic antibiotics with dental procedures, including routine dental repairs and cleanings. Many dental procedures require going below the gum line and thereby provide an opportunity for bacteria to enter the blood stream. Standard dental x-rays alone do not require antibiotic coverage.

The guidelines of the American Heart Association for endocarditis prophylaxis (prevention of an infection of the heart and valves) should be followed for people at increased risk for this infection, which includes all individuals with neutropenia. A wallet card can be downloaded from <http://www.americanheart.org/downloadable/heart/1023826501754walletcard.pdf>.

Heart Medication Precautions & Dental Treatment

Because patients with heart disease often are on multiple heart medications, the potential risk from drug interactions during dental treatment must be considered. For example, if adrenaline-containing local anesthetics are administered to patients taking heart medications such as beta-blockers, a drug interaction could induce a steep rise in blood pressure, which could trigger cardiovascular complications. During these steep rises in blood pressure, disturbances of cardiac rhythm could also be precipitated, and the use of adrenaline or a related vasoconstrictor should be considered very carefully.



Oral reactions to prescribed drugs, including altered taste, impaired salivary function and gingival hyperplasia (gingival overgrowth) may be seen in cardiac patients. Altered taste, typically described as 'metallic' may be noted. If an offending drug can be identified, it may be possible (in consultation with your physician) to discontinue it or give an alternative.

While abnormal growth of the periodontal tissue is mainly associated with plaque-related inflammation, some heart drugs have been implicated in causing gingival overgrowth, which may be brought to the dentist's attention because of pain, bleeding, or undesirable appearance.ⁱⁱ

Nitrous Oxide Use and the Barth Patient

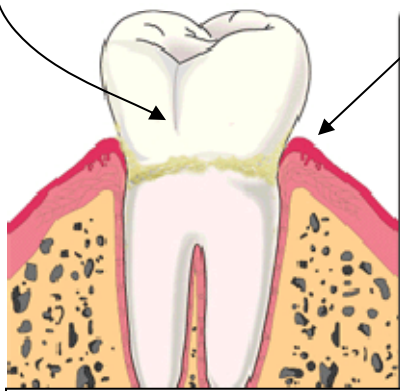
Nitrous oxide (laughing gas) has significant effects on the cardiovascular system. It may reduce the contractility of the myocardium and it may constrict pulmonary vessels, which can result in significant depression of the heart function. Consequently, nitrous oxide is not a safe sedative for individuals with Barth syndrome in a dental practice. Nitrous oxide should be administered only by anesthesiologists and only in a setting where the appropriate monitoring and resuscitation equipment is readily available.ⁱⁱⁱ

Why is preventive dental care so important for Barth syndrome Individuals?

Individuals with Barth syndrome fall into a "high risk" category with regard to infections due to neutropenia. Good dental hygiene is essential to reduce the potential for infection in the neutropenic patient. Because of the risk of endocarditis (infection of the inner surface of the heart), people with Barth syndrome should keep their teeth as healthy as possible to minimize the number of restorative dental procedures needed. Because periodontal disease (gum disease) provides a breeding ground for harmful bacteria, keeping gums healthy by practicing good oral hygiene is essential, and routine dental visits are a must! More frequent cleanings (2-4 times per year) at your dental office may be required to maintain optimal oral hygiene.

What is Plaque?

Plaque is a sticky substance containing mucus, food debris, bacteria, and other microorganisms and their products that binds to the tooth surfaces. Dental plaque is soft and easily removed by brushing and flossing the teeth. Removing plaque prevents bacteria from building up on your gums. Accumulation of plaque can lead to gum disease (gingivitis) and periodontal disease, as well as tooth decay. The key to preventing cavities is reducing the number of plaque bacteria. Millions of these bacteria live, work and play in our mouths. Here they feed on left-over food particles, producing acid in the process. It is this acid by-product that eats into tooth enamel creating cavities.



Plaque builds up around the tooth and causes inflammation

What is Gingivitis?

Gingivitis is inflammation of the gums. Common signs of gingivitis include red and swollen gums and the presence of bleeding while brushing and flossing. Bacteria in dental plaque cause gingivitis. This disease is reversible with good oral hygiene.

What is Calculus (Tartar)?

Calculus is dental plaque that has mineralized, which occurs when plaque is not removed from the tooth surface. Calculus can form above or below the gum tissue. The bacteria that stick to calculus can cause gum disease (gingivitis) or periodontal disease. Calculus cannot be removed by brushing and flossing. A dental hygienist checks for calculus and removes it with special instruments designed to clean the tooth surface without causing trauma to the soft gums.

What is Periodontal Disease?

Periodontal disease affects the periodontium (the supporting structures of the teeth). The cause of this disease is multifactorial, but the presence of bacteria in plaque certainly plays a major role. The supporting periodontal structures begin to breakdown. This can mean that part of the bone that supports the teeth or the ligaments that hold the teeth securely in place are destroyed. This disease is generally not reversible and may require treatment from a dental professional specializing in periodontal disease. Periodontal disease can develop as a result of poor daily plaque control (e.g. inadequate brushing and flossing). However, not everyone with poor brushing

Oral Hygiene Fact Sheet

The Barth Syndrome Foundation www.barthsyndrome.org

2 May 2008/ CAB, RIK

and flossing techniques will develop this condition. It is wise to visit your dental hygienist or dentist regularly to detect early stages of the disease and to prevent further damage.

Sugar Snack Facts:

- Frequent snacking on foods containing sugar increases the risk of getting cavities.
- Each time you eat sugar, plaque in the mouth combines with sugar to produce acids.
- These acid attacks on the teeth over time can destroy the tooth structure.
- Avoid developing a "sweet tooth" by limiting foods high in sugar.

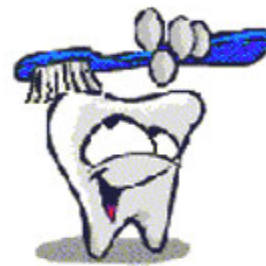Tips for Good Snacking Habits:

- Cut down on high-sugar snacks and offer snacks that are low in sugar such as vegetables, cheese, or pretzels. These do not promote tooth decay.
- Reduce the number of times a day that you eat sugar-containing food and snacks. With frequent snacks, the acidity of the mouth stays high, exposing the tooth to acid for extended periods of time. Frequent snacking will increase the risk of getting cavities more than eating the same amount at one sitting.
- Avoid soft, sticky sweets that lodge on and between tooth surfaces, such as toffee, dried fruits, etc. Sticky foods are retained in the mouth longer and, as a result, the tooth-destroying acid is produced for a longer period of time. Small amounts of sticky snacks increase the risk of getting cavities more than larger amounts of non-sticky foods.
- Natural sugars (found in breast milk, fruit, milk, bananas) have the same effect on your teeth as refined sugars (found in soda pop, ice cream, and cake). Because healthy foods containing natural sugars should not be avoided, brushing afterwards is important in the prevention of tooth decay.
- Don't give sugar-enriched foods that stay in the mouth and prolong the acid attack, such as gum, hard candies, lollipops, etc.
- If you serve sweets, serve them with meals, because increased saliva flow during meals helps neutralize the effects of sugar.
- Brushing and flossing after snacks and meals is important in preventing cavities that form from exposure to sugar.

Oral hygiene begins during infancy

Often parents think that brushing should not begin until a tooth is present in a child's mouth; however, oral hygiene begins long before that. Digestion begins in the mouth when enzymes produced by the salivary glands during feeding begin to break down foods, including mother's milk. The natural bacteria in the mouth are not harmful to the child, but the by-products of the bacterial breakdown of food can be. Cleaning can be accomplished simply by wrapping a thin clean washcloth or gauze around the finger and wiping excess food and milk from your child's mouth, especially between the gums and cheeks.

This provides an effective way to promote good oral hygiene in your child and also serves as a way to prepare your child early on for future brushing.



When teeth erupt

Because individuals with Barth syndrome are prone to infection, the eruption of teeth can be more problematic than in other children, causing fevers or even severe irritation of the gums. A cold compress or a piece of ice wrapped in a 2 x 2 gauze square can be applied directly to the eruption site. Through the numbing effect of the cold, this method can provide temporary relief - 20 minutes on, 20 minutes off. Tylenol or Advil can be given for the temporary relief of pain in dosages according to weight or age. Aspirin placed directly on the affected area will cause a chemical burn to the tissue and should be avoided. Prolonged pain, exaggerated irritability (over

one week) is unusual and may be caused by inflammation around an impacted or a partially impacted tooth. Prolonged pain is fairly common with eruption of the first permanent molars, the third molars, and the wisdom teeth. A dentist should be consulted for severe pain or fever associated with tooth eruption.

When a tooth comes through the gum line, it is known as tooth eruption. This is a normal process of the body. A child's first set of teeth are called the primary or deciduous teeth. As a child loses the primary teeth, the second set of teeth, known as the permanent or secondary teeth, come through the gum. Teeth are named for their location in the mouth and the function they serve. Incisors cut the food, and canines tear the food. Premolars crush the food, and permanent molars grind the food.

Children with Barth syndrome may have delayed tooth eruption. However, extreme delays should be reported to your son's pediatrician or dentist. On average, all 20 primary teeth have erupted by the age of 30 months (2 1/2 years).

UPPER TEETH		PRIMARY ERUPT	PERMANENT ERUPT
central incisor		8 - 12 mos.	7 - 8 yrs.
lateral incisor		9 - 13 mos.	8 - 9 yrs.
canine (cuspid)		16 - 22 mos.	11 - 12 yrs.
first premolar			10 - 11 yrs.
second premolar			10 - 12 yrs.
first molar		13 - 19 mos.	6 - 7 yrs.
second molar		25 - 33 mos.	12 - 13 yrs.
third molar			17 - 21 yrs.
LOWER TEETH		PRIMARY ERUPT	PERMANENT ERUPT
third molar			17 - 21 yrs.
second molar		23 - 31 mos.	11 - 13 yrs.
first molar		14 - 18 mos.	6 - 7 yrs.
second premolar			11 - 12 yrs.
first premolar			10 - 12 yrs.
canine (cuspid)		17 - 23 mos.	9 - 10 yrs.
lateral incisor		10 - 16 mos.	7 - 8 yrs.
central incisor		6 - 10 mos.	6 - 7 yrs.

Cleaning teeth after eruption

When teeth begin to erupt, an age-appropriate soft-bristled tooth brush should be selected for proper cleaning of the teeth. Toothpaste may be used when the child is old enough to understand that he should not swallow the toothpaste. Non-abrasive toothpaste is recommended when brushing. The American Dental Association (ADA) recommends brushing a minimum of 3 times a day. Remember each tooth has 5 surfaces. Brushing only cleans the chewing surface, the surface towards the tongue, and the surface closest to the cheeks and lips. When brushing is not possible, wipe or rinse particulate matter from child's teeth and gums.

Flossing is the only way to properly clean the surfaces between the teeth (the "interproximal surfaces") and remove food trapped between the teeth. Train your son early on to floss. This is especially important for a child with Barth syndrome, as they often have crowded teeth. The best prevention for interproximal caries is to floss regularly. Like brushing, one should floss after every meal.

A Water-pic is not an acceptable alternative to brushing and flossing. This device massages the gingival tissue (gums), however it does not remove the plaque, known to cause caries and periodontal disease (gum disease).

Bleeding can be caused by brushing and flossing. A soft bristled, age-appropriate toothbrush along with proper technique of brushing and flossing should minimize bleeding. However, sometimes pre-existing irritation of the tissue may cause bleeding even with the gentlest brushing. This irritation rarely occurs when proper oral hygiene techniques are used. Moreover, irritation also is commonly caused by inappropriate oral hygiene. Bleeding often occurs when the gum tissue has not been stimulated properly. Consult with your dentist for instructions for proper oral hygiene to avoid bleeding. Gum tissue should be stippled like an orange peel and pink. Red, inflamed gingival tissue is indicative of gum disease and should be evaluated immediately.

Proper oral hygiene is nearly impossible to maintain when aphthous ulcers are present, because they are extremely painful to the touch. When ulcers are present, it is important to consult with your dentist about alternative measures for brushing.

When first beginning to brush your child's teeth, you may find it awkward. A technique that may assist in proper brushing is to lay your son down restraining his arms and hands while brushing. Initially this may be a two-person job. However, with routine brushing and accolades, your son will find this an enjoyable routine. The key is to begin during infancy to introduce your son to oral hygiene.

Selection and care of a toothbrush and dental floss

- Select an age-appropriate, soft-bristled toothbrush.
- An electric toothbrush or Sonicare™ toothbrush may be used to reduce plaque as well.
- Select easy to use dental floss
 - The Glide™ or "Slide™" type floss – Johnson & Johnson, Reach Easy Slide™, Ultra Shred-Resistant Floss - will be easier to use. They slide more easily across the tooth surface and are less damaging to the gums, because less effort is needed to floss.
- Another device called Hydro Floss™ is a oral irrigator that has been proven to reduce interproximal plaque.
- Always thoroughly clean a toothbrush after every use to prepare it for the next use.
- Ideally, purchase a toothbrush sterilizer that uses UV rays to sterilize the family's toothbrushes. This is a far less burdensome procedure and an ideal solution to the need to keep toothbrushes clean and free of bacteria.
- Products such as Purebrush™ are 100% effective in killing bacteria and viruses.
- **NEVER** allow an individual with Barth syndrome to use anyone else's toothbrush or allow anyone in the home to use his toothbrush. Dispose of toothbrushes after three months of use.
- A traditional toothbrush cover is not recommended for a individual with Barth syndrome, because this is often a breeding ground for bacteria and viruses.



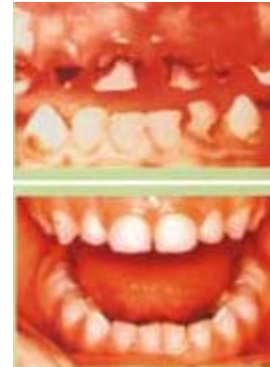Baby bottle syndrome

A common mistake parents make is to feed a bottle of milk, juice, or sugar water just prior to putting their children to bed. When the bacteria that team in the mouth during sleep are "fed" in this way, severe caries (cavities) develop quite rapidly. This is known as "baby bottle" syndrome. Often, baby-bottle caries are so severe that premature extraction (pulling) of the teeth is required. Premature extraction of the teeth may result in bone loss and shifting of the remaining teeth. The bone in the mouth is there to provide support for the teeth and its integrity must be maintained.

The baby teeth also serve as a guide for the eruption of the permanent teeth. However, because premature extraction of the teeth may be necessary in the event of severe caries, take every precaution to avoid this scenario.

Preventing caries in your child's mouth

- Always clean your son's mouth thoroughly after every feeding beginning in infancy
- **NEVER** put your child to bed with a bottle
- When offering your child a bottle prior to bedtime, use only water without anything in it
- Never give sugar water to your child
- Remember, milk, juice, and anything but plain water has sugar substances known to cause decay.
- Introduce your child to oral hygiene during infancy
- Schedule regular dental visits early in your son's life
- Ensure that your son is receiving appropriate doses of fluoride early on
- At 6 –10 months of age, your baby can begin drinking from a cup.



First visit to the dentist

The recommended age for a first visit to a dentist or pedodontist (pediatric dentist) varies. Selecting the appropriate pedodontist is as important as selecting any specialist who follows your son's health. Long before the first tooth erupts, it is prudent to call upon pedodontists in your area to determine when he/she recommends that you come to visit. Inform the pedodontist that your son has Barth syndrome and the medical issues it involves. Due to the special circumstance of your son's having Barth syndrome, the pedodontist may advise you to come for his first dental visit prior to the usual recommended age.

A pedodontist has special training in providing dental care for children and for children with special needs. Pedodontists' offices are specially designed for children, having smaller instruments, child-size chairs, and often, a child-friendly setting. Many pedodontists will not permit parents to accompany their child to the operatory setting. The reason behind this is that the child is more compliant when parents are not present. Another consideration when selecting a pediatric dentist is to determine the standards for controlling a non-compliant child. Some pedodontists use a technique called "hand over mouth". This is a practice of placing the hand over the mouth, but leaving the nose open to permit air exchange, when the child is crying, screaming, or otherwise non-compliant. Some parents do not find this acceptable; however, it is a widely accepted technique used in the pediatric dental community. Discuss with the pedodontist about the possibility of the practice "hand over mouth" being contraindicated with your Barth child.

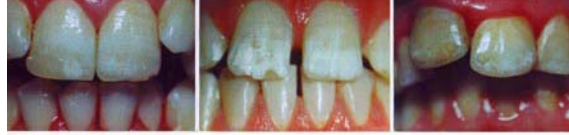Questions to ask when interviewing for a pediatric dentist:

- Do you permit parents to accompany children to the operatory during dental procedures?
- What techniques do you use when encountering a non-compliant child?
- What are your sterilization measures?
- Do you use sterile water when irrigating the child's mouth during dental procedures?

Fluoride use and treatments at the dental office

Toothpaste is not recommended for babies because they could swallow it and ingest too much fluoride, which can cause permanent white spots on the teeth. This is called dental fluorosis. A baby can get the proper amount of fluoride in areas where fluoride is in the water, whereas if the child resides in an area where fluoride is not found in the water, his pediatrician may prescribe

vitamins with fluoride. Additional fluoride in the vitamins is not recommended where there is adequate fluoride in the drinking water, because this too may cause dental fluorosis. It is important to consult with your local water utility to determine how much fluoride is in your son's drinking water and inform his pediatrician about the amount. This will assist your son's pediatrician in prescribing the proper supplemental vitamins for his overall health.



Fluoride is an important nutrient that strengthens tooth enamel. The strengthening of the enamel assists in the prevention of caries (dental decay, cavities). During routine prophylactic cleanings at the dental office, fluoride treatments are commonly administered. The ingestion of fluoride can cause nausea and vomiting. Because some ingestion of fluoride is to be expected with small children, trays with fluoride are loaded and placed in the child's mouth along with a suction device to reduce fluoride ingestion. With proper supervision of this momentary treatment, fluoride ingestion is minimized.

X-rays

X-rays are often recommended once a year as a way to detect interproximal caries (cavities between the teeth). Some dentists recommend bitewing x-rays more frequently if your child is prone to decay. This recommendation varies from patient to patient. The radiation absorbed during this procedure is equivalent to being outside for 30 minutes. Without bitewing x-rays, it is often impossible to diagnose interproximal caries.

Dental sealant

Dental sealants are thin, plastic films painted on the chewing surfaces of the back teeth (molars and premolars) and are highly effective in the prevention of tooth decay. Dental sealants are particularly effective on the back teeth, which contain many hard-to-reach pits and grooves that collect food debris and plaque build-up. Sealants are especially beneficial for children because their newly erupted, permanent teeth are most susceptible to cavities.

Restoration of caries

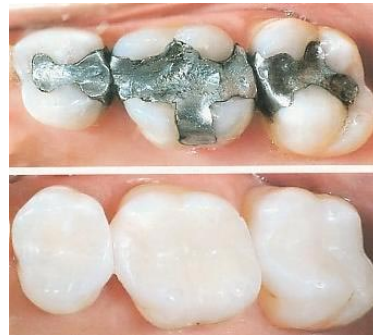Upon finding caries, the dentist will elect either to observe the tooth or to recommend a restoration of the tooth (filling). There are several dental materials and procedures that may be used for the restoration of teeth.

Filling Materials

Amalgam (silver filling)

This is a metal alloy of silver, mercury, and other metals that has been used in dentistry for many years. There is much controversy surrounding the use of amalgam, because trace amounts of mercury can be absorbed from the filling. It is prudent to read the literature about amalgam fillings that is produced not only by the dental societies, but also by independent laboratories and make a decision about the use of this material prior to its placement.

Your dentist may have a "mercury-free practice" which eliminates any need for research on your part. If not, discuss this with the dentist to make an informed judgment about the material being used in the restoration. Opinions vary widely about the safe use of amalgam.



**Top: Amalgam filling
Bottom: Composite filling**

Composite (tooth colored material)

Composite materials have improved tremendously over the years. Composites are now being used in the restoration of teeth throughout the mouth and no longer are considered as a material just used on front teeth. The composition of these materials bonds tightly to the tooth and wears nicely. However, because composite materials are often difficult to work with, many pediatric dentists elect not to use composites for restorations in the back teeth.

Rubber dam

During dental procedures, it is advisable for the dentist to use a rubber dam. This technique prevents the swallowing of materials during the procedure and also isolates the tooth from saliva. As the filling is carved into an anatomically correct restoration, some shavings will drop to the back of the mouth, often resulting in the ingestion of the material. The best measure to prevent the ingestion of these shavings is to use a rubber dam. Ask your dentist if he uses this technique.

Root Canal Therapy

Root canal therapy is designed to correct disorders of the dental pulp (the soft tissue inside the tooth that contains nerves, blood vessels, and connective tissue). The most common causes of pulpal nerve damage are:

- aggressive tooth decay (cavity) reaching down to the nerve or through deep fillings, which allows harmful bacteria to reach the nerve, causing infection and decay.
- a blow to a tooth or the jaw that causes damage to sensitive nerve tissue within the tooth.

If tooth decay penetrates into the pulp of the tooth, the entire pulp cavity must be cleaned out. Without treatment, an infection of the dental pulp will spread to the bone around the tooth. Once the tooth pulp has been removed, the tooth is no longer a vital tooth. This causes the tooth to become brittle and prone to break. As a result, the common practice is to recommend the placement of a crown on the primary or permanent tooth. A root canal procedure for a primary tooth does not take as long as one that is done in adults.

Dental Crowns

Dental crowning is a procedure whereby a strong cover is placed on a damaged tooth. The tooth may have been damaged by decay, or have had a previous restoration that has fractured. Root-canaled teeth are also crowned if sufficient tooth is missing or if the dentist feels that the tooth will last longer by protecting it with the crown. As previously mentioned, because the primary dentition serves as an important guide for permanent tooth eruption, it is important to maintain its integrity. Most often a pedodontist will use a pre-fabricated crown on a primary tooth. These are commonly composed of stainless steel for the back teeth and tooth-colored material for the front teeth. Such crowns should last until the primary tooth falls out. Crowns on permanent teeth may be composed of metal, porcelain, ceramic, or gold.

Extraction of teeth

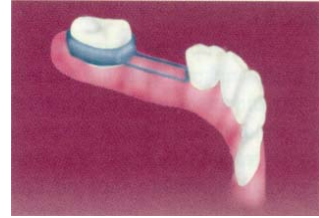
An extraction is the removal of a tooth that is non-restorable, non-useful, or harmful to the patient. Routine dental visits will assist in avoiding premature extraction of the teeth. However if one of the previously described situations is present, your dentist may recommend tooth extraction.

Abscess

When the pulp is diseased or injured and can't repair itself, it dies. The most common causes of pulp death are a cracked tooth and a deep cavity. Both of these problems can let germs (bacteria) enter the pulp and cause an infection inside the tooth. If a fractured tooth is left untreated; infection builds up at the root tip in the jawbone, forming an abscess. An abscess can cause permanent damage to the bone around the tooth.

Space Maintainer

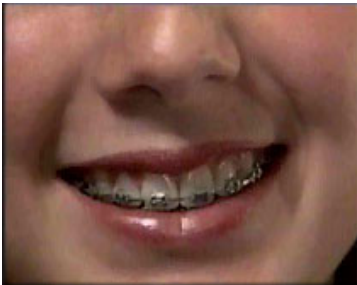A space maintainer is often recommended if a tooth must be removed prematurely. This prevents shifting of the teeth or crowding. This appliance serves to hold the place previously occupied by the deciduous tooth. Regular x-rays of your son's mouth following the eruption cycle will serve as a tool for the pedodontist to know when removal of this appliance is appropriate. Unexpected eruption of a permanent tooth between regular visits should be reported to the pedodontist.



Orthodontic Care

Orthodontics is the art of aligning the teeth, jaws, and bite to improve the patient's smile and oral health. It is recommended that a child be seen by an orthodontist early on to establish a baseline on the development of the child's arch and jaw. Orthodontic treatment uses braces or other appliances to put gentle pressure on the teeth and eventually move them into their right positions. If braces are needed, placement usually occurs between ages ten and fourteen years. The reason for this age is to allow time for the secondary teeth to erupt, but to begin the realignment while the jaw and head are still growing.

Routine visits to the orthodontist are not invasive, except for fitting and cementing bands on molar teeth (this procedure requires going below the gum and may provide an entry for bacteria).



Therefore, people with Barth syndrome should make their condition known to the orthodontist so that appropriate pre-medication can be given during the banding procedure.

The orthodontist may suggest other treatments before, during or after braces are put on the teeth. Other ways to solve your orthodontic problem that do not include braces may be suggested. These may include headgear, removable and attached appliances, and retainers.

Orthodontic care tips:

- All braces, brackets, and appliances should have every edge checked for roughness and be double-checked for exposed wires to make sure that no wires are sticking out.
- Appliances, brackets, and wires are a good place for bacteria to live, so they need good cleaning at least twice a day.
- Mouth sores will develop quickly when appliance edges become rough. Talk with your orthodontist about the best method to prevent and reduce rough edges. This will prevent or reduce mouth sores.
- Appointments should be scheduled in the first few days of the week, avoiding Friday or pre-holiday appointments. In this way, you will be able to see the orthodontist the next day to repair or smooth the appliance or wire if a problem develops.
- If you have to wait over a weekend or holiday with mouth sores caused by a rough wire, the orthodontic experience will be more uncomfortable.

ⁱ D.C. Dale, K. Welte, "Severe Chronic Neutropenia - The Role of Haematopoietic growth factors", 1993; <http://www.neutropenia.ca/about/scn.html>.

ⁱⁱ British Dental Journal Volume 189 No. 6 September 23, 2000 N. I. Jowett,¹ and L. B. Cabot,²; Patients with cardiac disease: considerations for the dental practitioner Cardio-active drugs and the safety of vasoconstrictor therapy.

ⁱⁱⁱ Michael Schlame, MD, Anesthesiology, NYU School of Medicine, New York, NY

Dental Glossary

Abscess - An infection of a tooth, soft tissue, or bone.

Amalgam - Also known as silver fillings, dental amalgams are comprised of a mixture of mercury (45 to 50 percent), and an alloy of silver, tin, and copper (50 to 55 percent).

Anesthesia - Partial or complete elimination of pain sensation; numbing a tooth is an example of local anesthesia; general anesthesia produces partial or complete unconsciousness.

Antibiotic Prophylaxis - refers to using antibiotics on patients who are at high risk for bacterial endocarditis, to help kill the bacteria that may enter the bloodstream during dental procedures.

Bite - Relationship of the upper and lower teeth on closure (occlusion).

Bite Wings- Caries (decay) detection x-rays.

Braces -Devices used by orthodontists to gradually reposition teeth to a more favorable alignment

bruxism - the condition of incessant grinding and clenching of the teeth, unintentionally, and at inappropriate times, most commonly while the patient is asleep.

Calculus - Hard residue, commonly known as "tarter," that forms on teeth due to inadequate plaque control, often stained yellow or brown.

Canker Sore- Mouth sore appearing whitish, often with a red halo, of ten to fourteen day duration.

Cleaning- Removal of plaque and calculus (tarter) from teeth, generally above the gum line.

Composite Resin- Also know as white fillings, a composite resin is a tooth-colored plastic mixture filled with glass (silicon dioxide) that is used primarily for cosmetic improvements of the smile by changing the color of the teeth or reshaping disfigured teeth.

Crown (cap)- Dental restoration covering all or most of the natural tooth.

Crowns are caps, covers, or restorations to replace the missing portion of a tooth. Sometimes used to correct bite problems or to replace missing teeth.

Cyst- A soft or hard tissue sac, hard or filled with fluid.

DDS - Doctor of dental surgery.

Decay (caries)- Destruction of tooth structure caused by toxins produced by bacteria.

Deciduous Teeth- Commonly called "baby teeth," the first set of (usually) twenty teeth.

Dental fluorosis - a condition that results from drinking overly fluoridated water that often causes the teeth to become discolored and the enamel of the teeth to look spotted, pitted, or stained.

Dentin- Inner layer of tooth structure, immediately under the surface enamel

Dentition- The arrangement of natural or artificial teeth in the mouth.

DMD - Doctor of dental medicine.

Enamel- Durable, hard, white outer layer of the tooth that covers and protects the dentin, the layer just beneath it. The hard tissue covering the portion of tooth above the gum line.

Endodontist- Specialist who treats injuries, diseases, and infections of the tooth pulp (nerve chamber).

Eruption- Process of teeth emerging through the gums.

Exfoliation- Process of shedding deciduous (baby) teeth.

Extraction- Removal of a tooth.

Filling- Restoration of lost tooth structure with metal, porcelain, or resin materials.

Fistula- Channel of pus from an infection site; a gum boil.

General Anesthesia- Controlled state of unconsciousness accompanied by a partial or complete loss of pain sensation, protective reflexes, and the ability to respond purposefully to physical stimulation or verbal command.

Gingiva- The gum tissue.

Gingivitis- Inflammation of gum tissue.

Gum Recession- Exposure of dental roots due to shrinkage of the gums as a result of abrasion, periodontal disease, or surgery.

Halitosis- Bad breath of oral or gastrointestinal origin.

Hygienist-Dental affiliate who cleans teeth and provides patient education; administers local anesthetic, nitrous oxide, and performs periodontal scaling.

Interproximal- referring to surfaces of adjoining teeth.

Local Anesthesia- Partial or complete elimination of pain sensation, in the immediate vicinity of its application or injection.

Malocclusion- An orthodontic problem that means "bad bite," including crowded, missing, or crooked teeth, extra teeth, or a misaligned jaw.

Mandible- the lower jaw.

Mastication- Process of chewing food.

Maxilla- the upper jaw.

Myofascial pain - the most common form of temporomandibular disorder; discomfort or pain in the muscles that control jaw function and the neck and shoulder muscles.

Nerve (root) Canal- Dental pulp; the internal chamber of a tooth.

Nitrous Oxide- A controlled mixture of nitrogen and oxygen gases (N₂O) that is inhaled by the patient in order to decrease sensitivity to pain. Also referred to as laughing gas.

Occlusion- Closure; relationship of the upper and lower teeth upon closure.

Oral Cavity- the Mouth.

Oral Hygiene- Process of maintaining cleanliness of the teeth and related structures.

Oropharynx - the part of the throat at the back of the mouth.

Orthodontics - The dental specialty that focuses on the development, prevention, and correction of irregularities of the teeth, bite, and jaws

Palate- Hard and soft tissue forming the roof of the mouth.

Pediatric Dentistry (Pedodontics)- A specialty in the field of dentistry -- dealing particularly with the oral health care of children from infancy through the teenage years.

Periodontist- Dental specialist who treats the gums and supporting soft and hard tissues, repairs and retains natural teeth, and surgically places dental implants.

Periodontal disease - also called gum disease, periodontal diseases are serious bacterial infections that can destroy the gums and the surrounding tissues of the mouth.

Permanent Teeth- (usually) Thirty-two adult teeth in a complete dentition.

Plaque - a thin, sticky film of bacteria.

Prophylaxis- Cleaning of the teeth for the prevention of periodontal disease and tooth decay.

Pulp - the soft tissue inside the tooth that contains nerves, blood vessels, and connective tissue.

Pulpectomy- Complete removal of the pulp (commonly done in children's teeth).

Restoration- Replacement of portion of a damaged tooth.

Root Canal- Common term for root canal therapy, also the interior space of the tooth root. A Root Canal procedure must be performed when the pulp within a tooth dies or becomes infected. The pulp is comprised of the tooth's nerve and blood supply and other soft tissues. Unfortunately, an infection in the pulp chamber or root canal will not heal by itself; it will only progress, destroying the pulp.

Rubber Dam- Soft latex sheet used to establish isolation of one or more teeth from contamination by oral fluids and to keep materials from falling to the back of the throat.

Saliva- Clear lubricating fluid in the mouth containing water, enzymes, bacteria, mucus, viruses, blood cells and undigested food particles.

Sealant - a thin, plastic film that is painted on the chewing surfaces of the back teeth -- the molars and premolars -- to prevent tooth decay.

Space Maintainer- Dental device that holds the space lost through premature loss of baby teeth.

Temporomandibular joints (TMJ) - the two joints that connect the jaw to the skull.

TMJ- the Temporomandibular Joint, the point where the lower jaw attaches to the skull.

Tooth Bud- Early embryonic structure that becomes a tooth.

Topical Anesthetic- ointment that produces mild anesthesia when applied to tissue surface.

Trauma- Injury caused by external force, chemicals, temperature extremes, or poor tooth alignment.

Unerupted Tooth- A tooth that has not pushed through the gum and assumed its correct position in the dental arch.

Xerostomia- Dry mouth or decrease in the production of saliva.

X-Rays- X-rays are used to reveal problems that cannot be observed visually or through any other means. They are a necessary part of regular dental checkups, and time has shown their use to be very safe. There are three types of dental x-rays: bitewing, complete series, and panoramic.